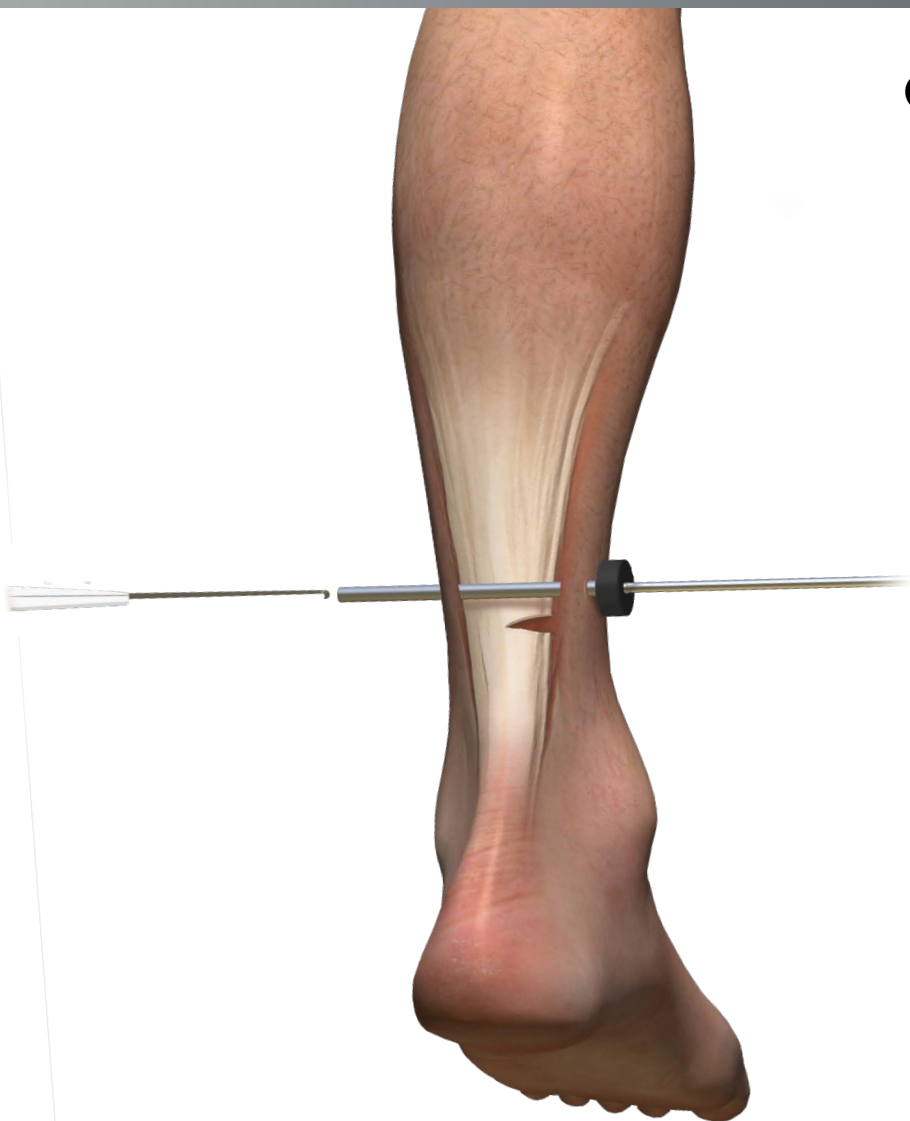


EGR™ Xpress

Endoscopic Gastrocnemius Recession

Operative technique



EGR Xpress

Endoscopic Gastrocnemius Recession

Table of contents

Introduction	3
Operative technique	4

This publication sets forth detailed recommended procedures for using Stryker devices and instruments.

It offers guidance that you should heed, but, as with any such technical guide, each surgeon must consider the particular needs of each patient and make appropriate adjustments when and as required.

A workshop training is recommended prior to first surgery.

Please remember that the compatibility of different product systems have not been tested unless specified otherwise in the product labeling.

For additional information please refer to the instructions for use (IFU), Ref. V15206 with each instrument. The surgeon must discuss all relevant risks, including the finite lifetime of the device, with the patient, when necessary.

Introduction

The EGR Xpress system is designed for the treatment of gastrocnemius equinus. Equinus is defined as a limitation of ankle joint motion and is a major contributor of many common foot disorders including hallux valgus, plantar fasciitis (fasciosis), Charcot arthropathy, hypermobile flatfoot (adult and pediatric), and hammer digit syndrome.

Operative technique

Step 1

Hemostasis is achieved with a thigh tourniquet and preparation and draping are according to standard operative protocol.

Position the cannula approximately 16cm proximal from the calcaneal insertion of the Achilles tendon. This is referred to as the mid-endoscopic zone.

Confirm anatomy by palpating distal to proximal, noting where the Achilles begins to fan out.

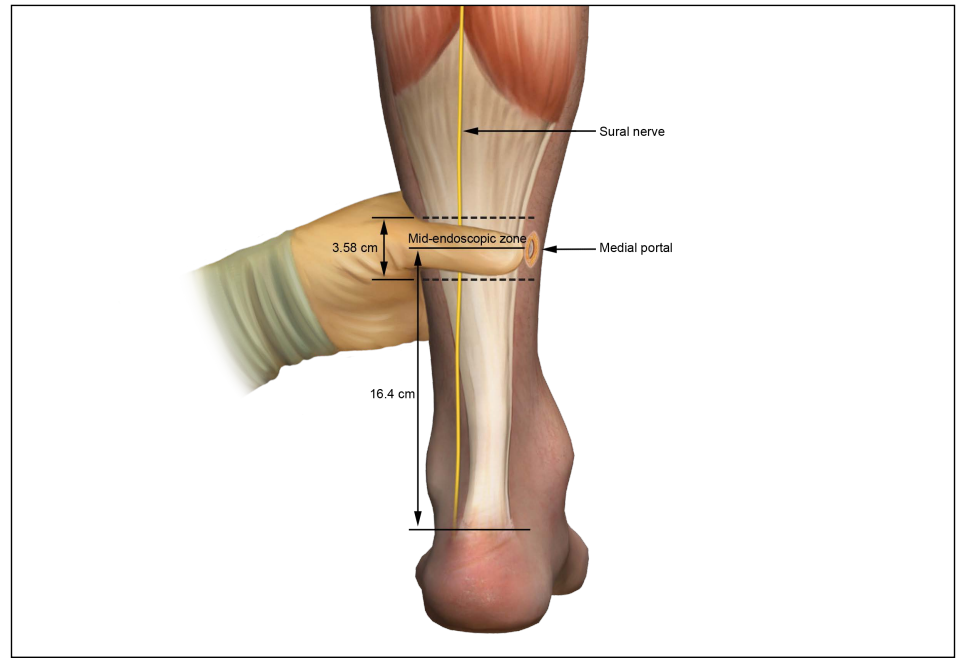


Figure 1

Step 2

Estimate the approximate location of the sural nerve and make a skin marking from the center of the popliteal fossa, between the two heads of the gastroc to 1cm posterior of the lateral malleolus at the level of the ankle.

On the medial aspect of the calf, use thumb to palpate anteriorly locating where the gastroc "falls-off" or ends. Place medial 1cm incision vertically.

Bluntly dissect through the subcutaneous fat down to the deep crural fascia.

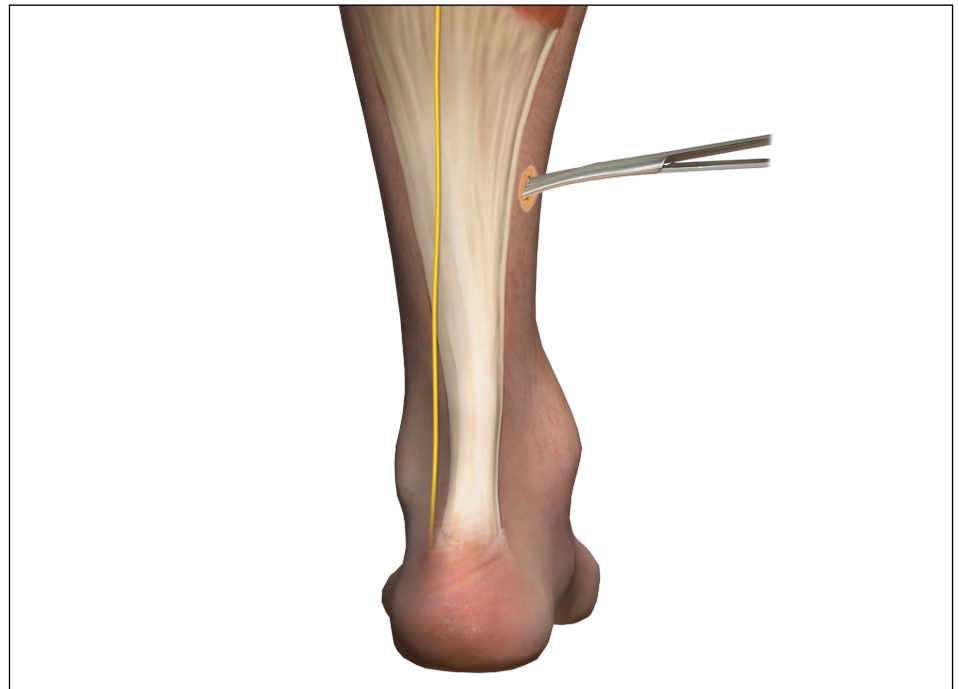

Figure 2

Step 3

Using the fascial elevator, separate the subcutaneous fat from the posterior aspect of the gastrocnemius.

Pass the fascial elevator completely across, tenting the tissue on the lateral aspect. There should be minimal resistance; if resistance is met, redirect elevator.

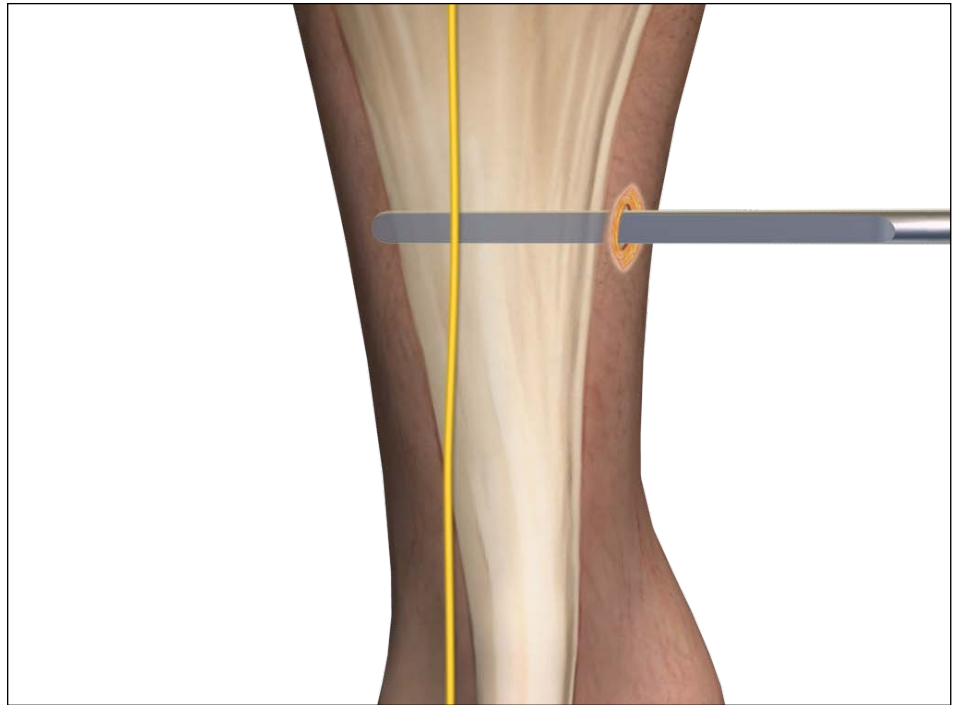


Figure 3

Step 4

Gently apply anterior pressure while passing the blunt obturator cannula assembly laterally. Once the tip of the obturator is palpated on the lateral aspect, a small incision is made over the tip of the obturator to allow exposure of the cannula through the skin. Remove obturator.

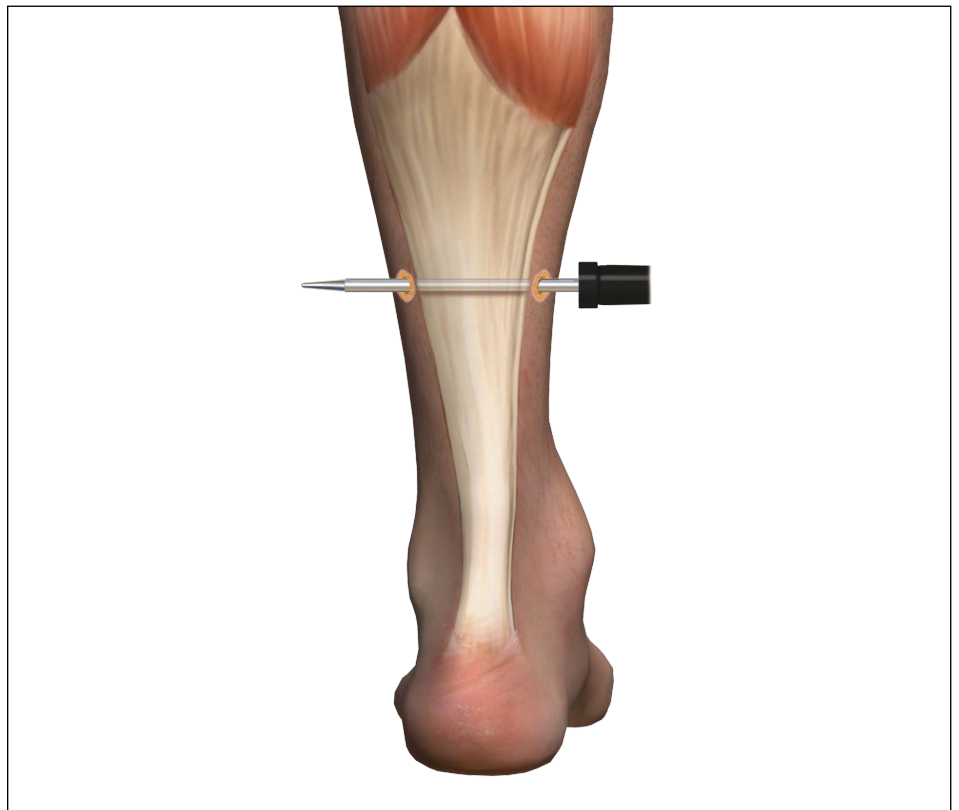

Figure 4

Step 5

Introduce a 4.0mm scope with 30 degrees bevel in medial cannula portal and insert hook blade through lateral portal of cannula. Advance hook blade medially, engaging the medial edge of the aponeurosis. Withdraw hook blade laterally, transecting the aponeurosis to the desired amount. The fibers of the muscle belly will be visualized beneath the gastrocnemius.

Skin closure is achieved with simple interrupted 5-0 nylon or prolene.

3cc of 0.5% Marcaine plain, and 1cc of dexamethasone phosphate are then placed into the surgical site.

The leg is wrapped in a small compressive gauze dressing and placed in a surgical boot.

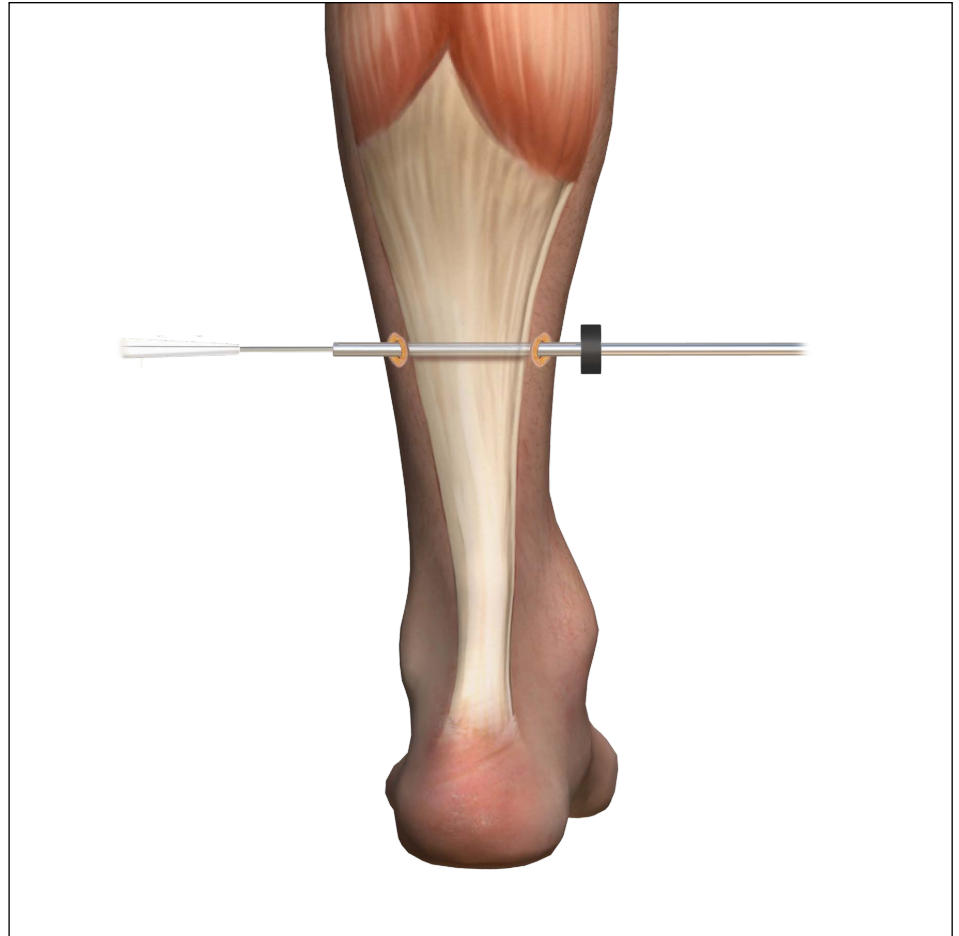


Figure 5

Step 6

Post operative management

Patients may remove the dressing the next morning after surgery and can shower for less than 5 minutes without immersing the foot, until sutures are removed. Sutures can be removed 10-14 days after surgery.

In EGR cases without other surgical procedures performed concurrently, the patient is allowed to walk immediately in a below the knee removable walking boot.

Patients are advised to remove their surgical boot the day of surgery and move their ankle actively and passively to decrease the chance of developing a DVT. They are encouraged to gently stretch the gastroc during the first four weeks, with knee extended.

Between 8-12 weeks, patients who have undergone isolated EGR can usually resume full athletic activity.

Some patients may experience muscle weakness for up to one year after the procedure.

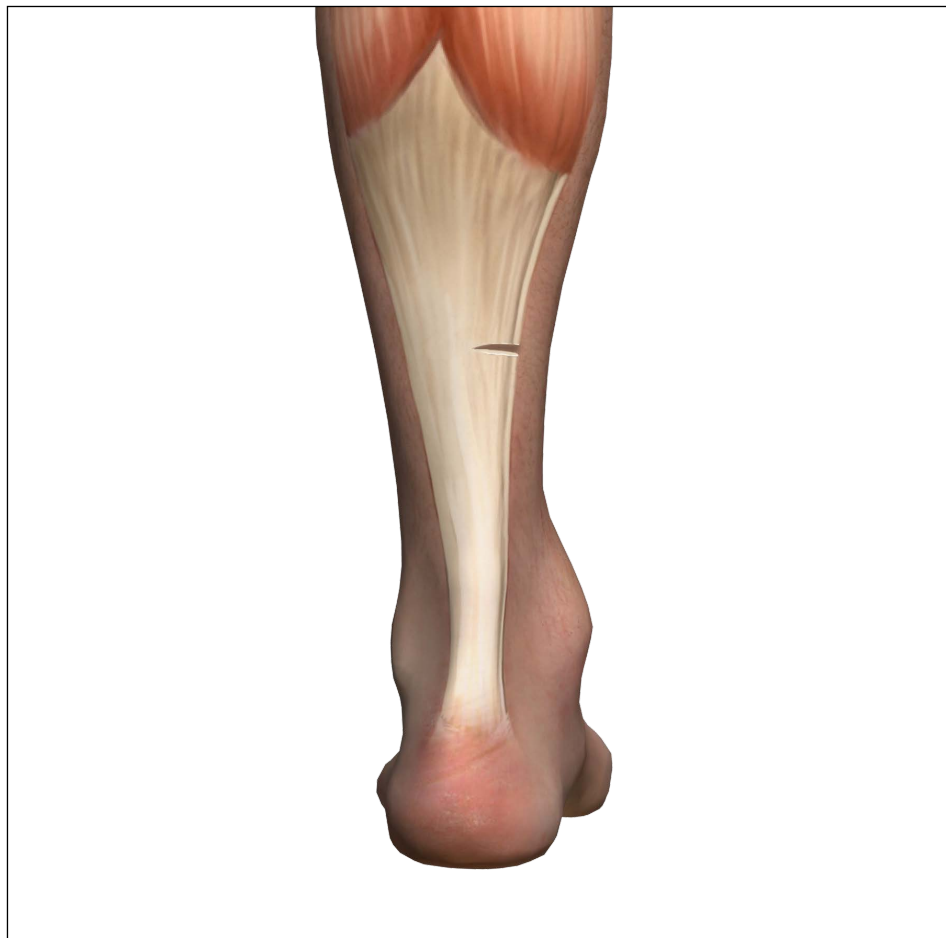

Figure 6

Foot & Ankle

This document is intended solely for the use of healthcare professionals. A surgeon must always rely on his or her own professional clinical judgment when deciding whether to use a particular product when treating a particular patient. Stryker does not dispense medical advice and recommends that surgeons be trained in the use of any particular product before using it in surgery.

The information presented is intended to demonstrate a Stryker product. A surgeon must always refer to the package insert, product label and/or instructions for use, including the instructions for Cleaning and Sterilization (if applicable), before using any Stryker product. Products may not be available in all markets because product availability is subject to the regulatory and/or medical practices in individual markets. Please contact your Stryker representative if you have questions about the availability of Stryker products in your area.

Stryker Corporation or its divisions or other corporate affiliated entities own, use or have applied for the following trademarks or service marks: EGR, Stryker. All other trademarks are trademarks of their respective owners or holders.

Content ID: OT-ST-17, 05-2016
Copyright © 2016 Stryker



Manufacturer:

Stryker GmbH
Bohnackerweg 1
2545 Selzach
Switzerland

stryker.com